



# A Woman Giving First Birth with Pubic Symphysis Rupture: A Case Report

**Rusnaldi<sup>1</sup>, Muhammad Budiman<sup>2</sup>**

<sup>1,2</sup>Department of Obstetrics and Gynecology, Universitas Syiah Kuala, Indonesia

Email: ruoemar@gmail.com

## **Abstract:**

Physical changes during pregnancy cause stretching of the pubic symphysis. Pubic symphysis rupture occurs when the joint widening is more than 10 mm which is confirmed by radiologic. The conservative and surgical are required to management of rupture of the symphysis. 25-year-old women with a postpartum birth canal tear using a vacuum. The patient felt severe pain and a lump in the pubic area. On examination, the uterus was 2 fingers below the navel, swelling in symphysis area, and pressure pain, and there were the labia and urethra lacerated without active bleeding. in laboratory tests, hemoglobin 7.3 g/dL, leukocytes 15,300/mm<sup>3</sup>, and platelets 255,000/mm<sup>3</sup>. The results of the pelvic x-ray examination are symphysiolysis. The patient underwent surgery with open reduction internal fixation (ORIF) and suturing the lacerated urethra by the surgical department. During the treatment, light mobilization and education on self and baby care were carried out. The wound was cleaned in 3 days and the urinary catheter was maintained for up to 14 days. The patient was discharged and carried out control every month for 6 months. Pubic symphysis rupture is one of the rare complications of labor due to multiparity, macrosomia, use of forceps, difficult labor, malpresentation, and trauma. The diagnosis is made when the intrapubic distance is greater than 10 mm on pelvic radiography. An MRI examination is preferred to assess for tissue tears. Operative internal fixation is performed when conservative therapy fails, soft tissue damage, and intrapubic distance of more than 25 mm. Pubic symphysis rupture is a labor complication due to the stretching of the symphysis. Surgical treatment is performed when conservative therapy fails.

## **Keywords:**

pubic symphysis rupture; delivery; internal fixation

## **I. Introduction**

A woman's physical changes occur during pregnancy. The enlargement of the uterus due to pregnancy causes changes in the musculoskeletal system to provide space and passage for delivery to the fetus. Changes occur in the size of the pelvis and stretch of the pubic symphysis, which can be seen from the enlargement of the pubic symphysis joint. This has started happening since the beginning of pregnancy and will return to normal size after delivery.

Still Birth is the death of a baby with a gestational age of 28 weeks or more, but coming out of the uterus there are no signs of life. Infant death is the death of a child of less than one year. Infant mortality is measured as the infant mortality rate which is the number of child deaths below one per 1000 live births (Syarief, in Nilawati, 2020). According to WHO stillbirth is the birth of a baby whose time is enough when it comes out of the uterus without any signs of life such as, the absence of a heartbeat, no breathing and no muscle movement (WHO, in Nilwati, 2020).

Health is a very important element of the quality of life in national development. The national health system has established that the goal of health development is to increase

awareness, willingness, and ability to live healthy for everyone so that a high degree of public health can be realized - high human resources, as an investment for socially and economically productive development. -Health Law No. 36 of 2009. (Hasibuan, 2020).

Maternal and Newborn Health is important to be improved and as a leading indicator in health (Madan et al., in Rildayani, 2020). The high number of maternal deaths in several regions of the world, shows the gap in access to health services between developed and poor countries. Maternal deaths occur as much as 99% in developing countries and more than half of these deaths occur in Africa and sub-Saharan, and nearly one third occur in the South Asian continent. More than half of maternal deaths occur in environments with poverty and humanitarian problems (WHO, in Rildayani, 2020). Judging from the difference in the magnitude of death between developed and developing countries, the risk of lifetime maternal mortality in developed countries is 1: 3300, while deaths in developing countries are 1:41 (United Nations Children's Fund, in Rildayani, 2020).

The pubic symphysis is a non sinovial joint that connects the right and left superior pubic rami which are tied with 4 pubic ligaments and fibrocartilage to maintain a stable position of the pelvic bones. The pubic symphysis joint is very limited in movement and will be dilated during pregnancy due to hormones. The enlargement of the pubic symphysis ligament and sacroiliac joint has occurred since the first trimester and is getting bigger during the second and third trimesters and will return to normal size postpartum. The pubic symphysis dilation will normally occur in about 1-3 mm and will not cause maternal symptoms.

One of the complications of large fetal size or fetal distortion is pubic symphysis rupture that occurs during labor. Pubic symphysis rupture occurs when the joint widens more than 10 mm and is associated with deformity and pain. This has been reported from 1 in 300 to 1 in 30,000 deliveries. The size of the widening is still underreported because the symptoms are mild and resolve without treatment. An intrapubic dilation of more than 10 mm is the threshold for symptom development, although the magnitude of the dilation does not necessarily correspond to reports of pain. The diagnosis of pubic symphysis rupture was carried out with clinical symptoms and confirmed by radiological examination.

The most common clinical symptom of pubic symphysis rupture is postpartum pain in the pubic symphysis area radiating to the thigh area. Physical examination shows a lump in the suprapubic area and the patient will appear more strained when walking. Sometimes there will be a "pop" sound during labor which is the sound of the joint during rupture.

There are 3 categories of orthopedics due to trauma to the pelvic ring, type A which will return to stability even though a fracture occurs, type B is the result of external and internal rotation causing "open book" and "bucket handle" fractures, and type C which is unstable due to heavy force so complete damage to the pelvic ring. In most cases, pubic symphysis rupture is classified as an "open book" type B and is treated according to its severity, type, and surrounding musculoskeletal damage. The obstetric instability of the pubic symphysis postpartum was comparable to that of an anteroposterior compression (APC) injury. There are 3 categories in APC, namely APC I with less than 2.5 mm dilation with intact anterior sacroiliac ligaments, APC II symphysis enlargement of more than 2.5 mm, and intact posterior sacroiliac ligaments, and APC III associated with sacroiliac damage. Most of the cases in Osterhoff's (2012) study found that the incidence of rupture occurred in the APC II category.

The initial management of pubic symphysis rupture is conservative and yields good results in most cases. Conservative therapy begins with placing a bandage in the pelvic area, covering a small part of the intapubic area, bed rest in a lateral recumbent position, and medical therapy. Pelvic belt insertion is very effective with placement directly anterosuperior to the iliac spine and can be used as repositioning therapy for short periods. Medical therapy includes anti-inflammatory therapy, narcotics, and injection of corticosteroids, chymotrypsin, and lidocaine intrasymphysis.

Physiotherapy is performed during bed rest which aims to reduce complications during bed rest more than 6 weeks which can cause bacterial infections such as pressure ulcers, pneumonia, urinary tract infections, neuropathy, and joint stiffness. Furthermore, the psychological effect on sequelae can increase morbidity and decrease the ability of mothers to care for themselves and their babies.

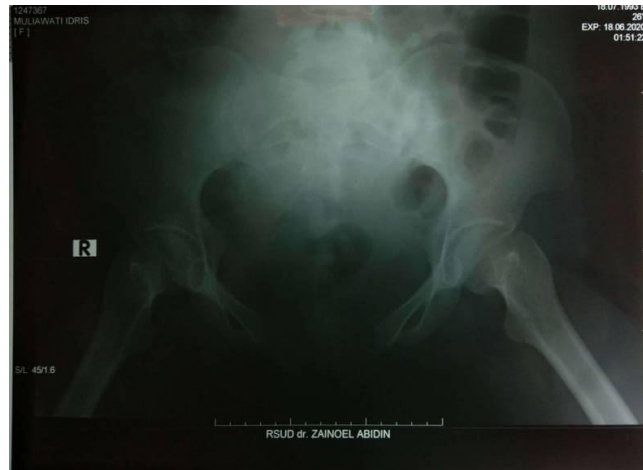Handling both internal and external stabilization surgery is needed to reduce maternal morbidity. Surgical treatment is very rarely performed due to the failure of conservative therapy, damage to surrounding tissue, or a widening of more than 25-40 mm. Surgical interventions can provide good results and reduce hospital stay, speed up maternal mobilization, and increase the mother's ability to care for herself and her baby.

Mobilization can reduce the likelihood of obstruction of blood flow and stress injury. External fixation is carried out for a short period and is performed when internal fixation cannot be carried out such as high contamination from the pelvic area. External fixation can reduce comfort, there is still pain and the presence of sores on the skin. Internal fixation can be done by installing 4, 6, or 8 holes of plates and screws depending on how much reduction is needed to accelerate the healing of the ligaments better.

## II. Case

A 25-year-old female patient was referred from the regional hospital with tearing of the birth canal after her first delivery using a vacuum. Labor was led by a specialist obstetrician and delivery lasted 2 hours after complete opening due to dystocia. A vacuum-assisted delivery and a live boy borned of 3200 grams. After delivery, a birth canal tear was found with active bleeding then suturing and bleeding control were performed. She felt pain and lump in the pubic area. She claimed to have no previous history of hip trauma. Subsequently, she was referred to the Banda Aceh hospital after external stabilization was done using a dressing and no active vaginal bleeding was found. She was also given painkillers and anti-bleeding injections upon referral.

The patient was examined again in the obstetry room at the dr. Zainoel Abidin General Hospital and there is still a pain in the pubic area. On examination, it was found that the patient was fully conscious, generally weak, looked moderate in pain, blood pressure 114/76 mmHg, pulse 126 times per minute, and breaths 20 times in a minute. Obstetric examination showed the uterine fundal height was 2 fingers below the navel, swelling in the symphysis area and pain when pressing, and there was a tear in the labia minor and urethra without any bleeding. External stabilization was maintained until X-rays was performed. The chest and abdomen examination were within normal limits. Laboratory tests showed hemoglobin levels of 7,3 g / dL, leukocytes 15,300 / mm<sup>3</sup>, and platelets of 255,000 / mm<sup>3</sup>. Pelvic x-ray examination was with symphysiolysis results. The patient was then consulted wth the surgical urology and orthopedic department for surgery.



**Figure 1.** Pelvic X-Ray Examination of the Patient

### III. Discussion

Several physical changes occur normally during pregnancy. Enlargement of the uterus due to pregnancy, causing stretching of the surrounding tissue which causes musculoskeletal changes in pregnant women. The pubic symphysis is a synovial joint separated by fibrocartilage tissue and bound by 4 pubic ligaments. In the advanced phase of pregnancy, the body's skeleton will change in preparation for labor, namely the widening of the pelvic joints. The pubic joint dilation also involves changes in the pubic symphysis and sacroiliac joints, which normally have started since the first trimester of gestation and widened in the second and third trimesters and will return to normal postpartum size.

The pubic symphysis dilation ranges from 1 to 3 mm and generally occurs without complaint. Pubic symphysis tear is one of the rare complications at the time of delivery which reports 1: 300 to 1: 30,000 deliveries. Little is known about major reports of enlargement because it is mostly mild and resolves on its own. Pubic symphyseal dilation of more than 10 mm is associated with a threshold that can cause complaints. Although symphysis rupture is rarely a complaint, proper diagnosis and therapy will improve the maternal condition. Knowing the risk factors, diagnostic modalities, and therapy is needed to prevent complications of this condition.

In a meta-analysis study, the risk factors for symphysis rupture were discussed in 17 articles. There are also known risk factors associated with symphyseal rupture including multiparity, macrosomia, cephalopelvic disproportion, forceps delivery, joint weakness due to increased pregnancy hormones, connective tissue disorders, difficult labor, malpresentation, history of pelvic trauma, Mcroberts maneuver, and increased pelvic cycles as a result uterine contractions during the second phase of labor. There were differences of opinion regarding the multiparity that resulted in progressive weakness of the pubic symphysis each delivery, but multiparity was not a consistent factor in symphysis rupture compared to primiparous patients. Macrosomia and the length of the labor phase are closely associated with an increased risk of symphysis rupture.

In this case, the symphysis rupture occurred in a 25-year-old woman with a primipara pregnancy. Vaginal delivery lasted 2 hours after complete opening which was thought to be due to cephalopelvic disproportion and distortion so that delivery was assisted using a vacuum. The patient had no history of previous trauma. Symphysis rupture occurred due to mismatching of the size of the fetus and birth canal so that labor was prolonged and required interventions that

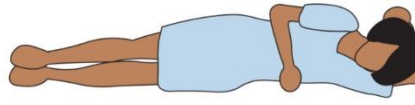
increase the risk of rupture. The diagnosis of pubic symphysis rupture is obtained antepartum, intrapartum, and 48 hours postpartum. Symptoms of a symphysis rupture are suprapubic pain, swelling and edema where the pain can radiate to the legs, thighs, and buttocks. Sometimes a lump is felt in the pubic symphysis area. The pain will increase when applying pressure on both trochanters, but this is not necessary because it can cause morbidity. In labor under spinal or epidural anesthesia, the pain of symphyseal rupture can be disguised and complicate initial diagnosis.

In a retrospective study, Yoo et al (2014) compared women with peripartum pubic symphysis diastasis with controls in 4140 women with risk factors. The diagnosis is made by an intrapubic distance of more than 10 mm at the shortest point on the anteroposterior pelvic radiograph. This study compared the patient's age, gestational age, number of gestations, type of delivery, infant weight, and infant gender into two groups. In univariate analysis, there were significant differences between the control group and the diastasis group on parity factor ( $p = 0.016$ ), single fetus versus twins ( $p = 0.003$ ), and type of delivery ( $p = 0.034$ ). In the multivariate analysis, there were significant differences between single and multiple fetuses (odds ratio, 9.2; 95% CI, 2.52-33.57;  $p = 0.001$ ) and type of delivery (odds ratio, 12.6; 95% CI, 1.48-100.46;  $p = 0.020$ ).

In this case, the patient was pregnant with a single fetus, gave birth with vaginal delivery and assisted with a vacuum. The use of vacuum was due to difficult labor due to disproportion and distortion thus increasing the risk of symphysis rupture. The patient complained of postpartum pain which was also caused by an injury to the birth canal that had been sutured. Pain had decreased after being given painkillers before the patient referred. On physical examination, there was swelling in the symphysis area and pain on pressure. On pelvic radiographs, symphysis enlargement was found with the diagnosis of symphysiolysis.

Classical radiological studies such as pelvic x-rays or computed tomography (CT) scans have limited visualization of bone separation. One study and several case reports suggested magnetic resonance imaging (MRI) to assess pelvic joint loops and assess soft tissue damage associated with symphysis rupture. Wurdinger et al's (2002) studied of the use of MRI compared normal and pathology of pelvic circles in 19 postpartum women with 11 control women of the same age. In this study, it was found that MRI helped diagnose symphyseal rupture and that there was little change in pubic cartilage damage in asymptomatic patients who initially suspected normal postpartum. Kurzel et al (1998) described 2 cases of symphysis rupture with MRI examination which showed a greater intrapubic stretch and a better picture of soft tissue damage than on ordinary x-ray images.

The initial treatment for postpartum symphysis rupture is conservative treatment by performing pelvic stabilization with external fixation using a belt over the anterosuperior iliac spine to reduce pain, reduce stretch, and facilitate patient mobilization. Patients are advised to bed rest while in the recumbent lateral position, which is a supine position on one side. This allows less stretching of the symphysis and less pain. Physical therapy with light exercise to reduce the risk of complications from lying down for a long time, namely pressure ulcers, pneumonia, urinary tract infections, neuropathy, and joint stiffness. Medical therapy is given in the form of anti-pain and anti-inflammatory. Mothers are trained to provide care for themselves and their babies to reduce the risk of psychological effects due to pain and reduced activity.



**Figure 2.** The lateral recumbent position

Kharrazi et al (1997) described the efficacy of conservative therapy in symphysis rupture. Kharrazi described 4 case reports with peripartum symphysis rupture and sacroiliac joint rupture with an intrapubic distance of more than 60 mm. At follow up, the patient still complained of pain and inability to move after 17 mm intrapubic distance. In these four cases, there was a delay in healing due to the absence of consultation and surgery from the surgical department. Kharrazi recommends conservative treatment for cases with an intrapubic distance of less than 40 mm, while for a distance of more than 40 mm it is recommended for surgery. Phupong and Sudjai (2003) described a case report of a pubic symphysis rupture that was diagnosed during the intrapartum phase. The patient gave birth vaginally and received conservative therapy. This case report explained that the incidence of symphysis rupture can occur with vaginal delivery and conservative therapy was recommended from the intrapartum period.

Surgical stabilization can be performed by external or internal fixation of pubic symphysis ruptures. Operative stabilization is rarely performed and is indicated when conservative therapy fails, there is soft tissue damage around the pubic area, and an intrapubic distance of more than 25 mm. Operative interventions can provide better results and can shorten hospital care and speed up mobilization of mothers so they can take care of themselves and their babies. External fixation is only performed when there is a contraindication to internal fixation, such as contamination of the pelvic area. External fixation is rarely performed because of maternal discomforts such as pain due to external fixation pressure and risk of skin infections.

On physical examination of this case, there was a birth canal injury in the labia minor and urethral, the patient was consulted to the surgical department for examination and surgery. The patient was operated an internal fixation operation using ORIF by an orthopedic and a urologist sutured urethral injury. The operation was continued by an obstetrician to suture the wounds of the birth canal and minor labia. Postoperatively the patient was taught a recumbent lateral position and light mobilization. Furthermore, the patient was also taught to take care of themselves and gave breast milk to her baby. The patient was admitted for 5 postoperative days and discharged with maintaining a urinary catheter for 14 days. The patient was advised to follow up every month for 6 months to monitor the progress of the wound and internal fixation.

#### **IV. Conclusion**

Pubic symphysis rupture is one of the labor complications that occur due to stretching of the symphysis due to prolonged labor and cephalopelvic disproportion. Complaints of symphysis rupture can occur antepartum, intrapartum, and postpartum in the form of pain and a lump in the pubic area. The diagnosis of symphysis rupture can be confirmed by radiological examination. The initial treatment for symphysis rupture is conservative therapy in the form of pelvic stabilization and pain relief. Surgical treatment is given if conservative therapy is unsuccessful, there is soft tissue damage and the intrapubic distance is more than 25 mm.

## References

- Bhardwaj A, Nagandla K. Musculoskeletal symptoms and orthopaedic complications in pregnancy: pathophysiology, diagnostic approaches and modern management. *Postgrad Med J*. 2014;90:450–460.
- Cicek H, Keskin HL, Tuhanioglu U, Kilicarslan K, Ogur HU. Simultaneous Disruption of The Pubic Symphysis and Sacroiliac Joint During Vaginal Birth. *Case Rep Orthop*. 2015;812132.
- Gräf C, Sellei RM, Schrading S, Bauerschlag DO. Treatment of Parturition Induced Rupture of Pubic Symphysis after Spontaneous Vaginal Delivery. *Case Report in Obstetrics and Gynecology*. 2014:485916.
- Gräf C, Sellei RM, Schrading S, et al. Treatment of parturitioninduced rupture of pubic symphysis after spontaneous vaginal delivery. *Case Rep Obstet Gynecol*. 2014;2014:485916.
- Hasibuan, S.,M. et al. (2020). Relationship of Family Income and Family Support with Maternal Reference in Pregnant Women in Pantai Cermin BEmONC, Langkat District, 2019. *Budapest International Research and Critics Institute-Journal (BIRCI-Journal)*. P. 486-493.
- Herren C, Sobottke R, Dadgar A, Ringe MJ, et.al. Peripartum Pubic Symphysis Separation- Current Strategies in Diagnosis and Therapy. *elsevier*. 2015;48(6):1074-1080.
- Jayaraman JK, Prabha G, Nallianna I. Post Partum Diastasis of Pubic Symphysis. *J Clin Diagn Res*. 2015;9(9)09-10.
- Julio J, Seger E. Post Partum Management of Severe Pubic Diastasis. *Clinical and Experimental Obstetrics and Gynecology*. 2017;0390-6663.
- Kelsey LS, Everett FM, Shahryar A. Pubic Symphysis Rupture and Separation During Pregnancy. *CME Review Article*. 2015.
- Nilawati, et al. (2020). The Analysis of Infant Death Determinants in Aceh Besar Regency of 2019. *Budapest International Research and Critics Institute-Journal (BIRCI-Journal)* Vol 3 (3): 1570-158.
- Pires RES, PJ Labronici, V Giordano, et al. Intrapartum Pubic Symphysis Disruption. *Annals of Medical and Health Sciences Research*. 2015;5(6):476-479.
- Rildayani, et al. (2020). The Effect of the Comprehensive Midwifery Care Model with the One Student One Client (OSOC) Approach to Birth Outcomes in North Aceh Regency. *Budapest International Research and Critics Institute-Journal (BIRCI-Journal)* Vol 3 (3): 1676-1682.
- Yoo JJ, Ha YC, Lee YK, et al. Incidence and risk factors of symptomatic peripartum diastasis of pubic symphysis. *J Korean Med Sci*. 2014;29:281–286.